

# Canine Cataract Surgery

Technology and technique follow the human cataract experience.

BY CYNTHIA COOK, DVM, PHD, DIP. ACVO

Cataracts are the most frequent cause of blindness in dogs. Most cataracts are inherited and affect dogs older than 5 years of age. Commonly affected breeds include the American cocker spaniel, poodle, Boston terrier, miniature Schnauzer, Bichon Frise, and Labrador retriever. Typically, genetic lenticular opacities are bilateral and slowly progressive. Rapidly progressive cataracts commonly occur in dogs with diabetes mellitus (Figure 1). Secondary lens-induced uveitis is a frequent finding that may complicate pre- and postoperative management (Figure 2).

Keeping in mind the relative contribution of vision to a normal dog's lifestyle, there are many ways in which the typical canine patient differs from a human patient presenting for cataract surgery. Owners often do not bring their pet to the ophthalmologist until the signs of impairment are significant. Dogs are able to accommodate for their reduced vision, particularly when the impairment is monocular and they are in a familiar environment. Owners may first notice their pet's hesitation when it is descending stairs or has difficulty catching a toy or treat. Some dogs may exhibit changes in temperament, such as becoming more aggressive because they are more easily startled.

## BACKGROUND

Phacoemulsification with IOL implantation has been the standard of treatment for cataracts in dogs for the past 25 years. Veterinary ophthalmologists used IOLs (13.00 D) designed for humans until keratometry and A-scan biometry demonstrated very different parameters necessary to achieve emmetropia in aphakic dogs.<sup>1-3</sup> The evolution of IOLs for dogs, however, has closely followed advances in the human field. A canine posterior chamber IOL is 40.00 to 41.00 D, with a biconvex optic measuring 6 to 7 mm in diameter, a peripheral edge to limit posterior capsular opacification (PCO), and a haptic-to-haptic length of 12 to 16 mm.<sup>4</sup> Biometry and keratometry (K) readings vary surprisingly little across the wide range of dog breeds.<sup>2,5</sup> IOL parameters have also been determined for the feline eye.<sup>6</sup> In dogs, axial length

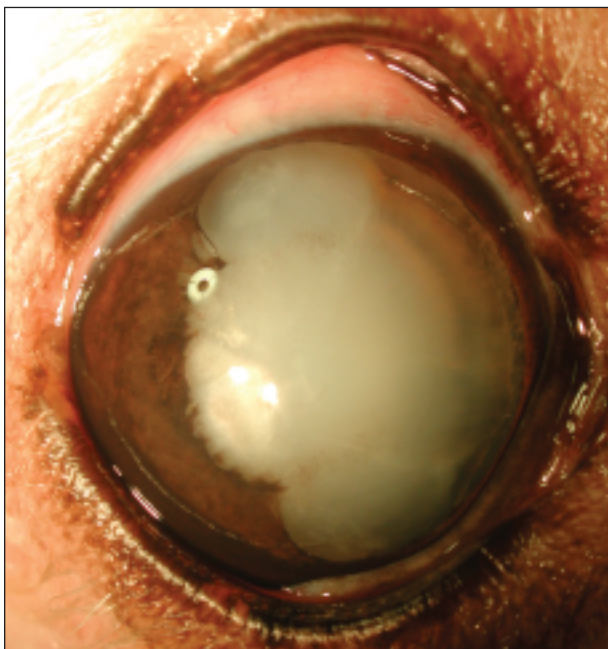


Figure 1. This 9-year-old diabetic dog has bilateral mature cataracts. These rapidly progressive opacities are associated with marked visual impairment.

ranges from 19.5 to 21.9 mm, and K values range from 37.40 to 41.70 D.

In clinical practice, veterinary ophthalmologists do not obtain individual biometry and K readings for each animal. There is a limited number of IOL manufacturers, and considerations related to volume and cost restrict the sizes and styles of lenses available to surgeons. Most stock only a few types of IOLs and use a "one size fits all" approach, which corrects most dogs' vision to within a satisfactory range of 1.00 to 2.00 D of emmetropia.<sup>4</sup> Lens materials may be PMMA, acrylic, HEMA, or silicone. Because veterinary ophthalmologists consider postoperative astigmatism to be a relatively small obstacle to the goal of near emmetropia, they are not as strongly motivated toward small-incision surgery. PCO, however, remains a significant postoperative complication that is driving a move toward materials other

## CATARACT SURGERY FEATURE STORY



**Figure 2.** Chronic lens-induced uveitis results in posterior synechia, hyperpigmentation of the iris, more frequent zonular disruption, retinal degeneration, and postoperative glaucoma.

than PMMA.<sup>7</sup> The IOL's design plays a part, and the lenses veterinary ophthalmologists use commonly have square edges to reduce PCO.

Cost can be a limiting factor in clients' decision to seek surgery for their pet. Third-party payment for veterinary care occurs in fewer than 5% of our patients. The total cost of bilateral cataract surgery with replacement IOLs is approximately \$3,400. Replacement IOLs range in price from \$25 to \$150, with PMMA IOLs being the least expensive.

### THE PROCEDURE

Canine cataract surgery is performed as an outpatient procedure under general anesthesia. The dogs' eyes are medicated with topical antibiotics, corticosteroids, and NSAIDs for several days prior to surgery. I administer systemic NSAIDs preoperatively and induce mydriasis with tropicamide and phenylephrine. Preoperative hydromorphone is administered. General anesthesia is induced with midazolam and propofol and maintained with isoflurane or sevoflurane. A neuromuscular blockade is achieved with pancuronium; positive-pressure ventilation is maintained. Many animals presenting for cataract surgery have bilaterally mature cataracts that prevent the direct visualization of the fundus. Once the patient is under general anesthesia, I routinely perform electroretinography; ultrasonography may also be performed.

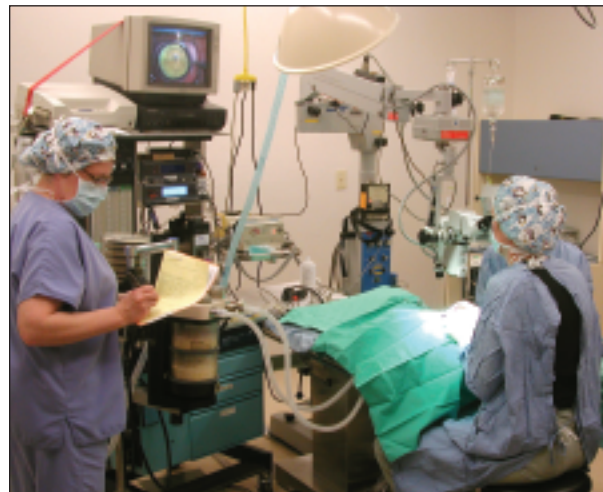I create a limbal incision by making a groove of 50%

thickness.<sup>8</sup> The thickness of a dog's peripheral cornea is 0.6 mm, but it becomes thicker with age. The incision's length depends on the type of IOL to be implanted. I enter the anterior chamber with a 2.8-mm sapphire or diamond blade. I use viscoelastic (chondroitin sulfate and/or hyaluronic acid) to maintain the anterior chamber. After creating the continuous curvilinear capsulorhexis, I perform hydrodissection.

Most canine cataracts are quite dense. They most closely resemble the hardness of a brunescens human cataract but are white (Figures 1 and 2). Many veterinary ophthalmologists obtain phaco units as they are retired from surgery centers for humans, so the machines are often several generations older than the latest model. Veterinary surgeons use both peristaltic and Venturi systems, depending on their preference. They may use many of the phaco techniques commonly employed for dense human cataracts, including phaco chop and other two-handed approaches<sup>9</sup> (Figure 3). Phaco times may be several minutes, depending on the hardness of the lens. I perform I/A and capsular polishing before enlarging the incision (if needed) and implanting the IOL (Figure 4). I use a continuous pattern of 9-0 polygalactin suture material. Finally, I administer carbachol intracamerally<sup>10</sup> to induce miosis and reduce postoperative pressure spikes. Patients also receive subconjunctival triamcinolone to aid in the management of postoperative inflammation.

### POSTOPERATIVE CARE

Dogs wear an Elizabethan collar for the first 1 to 2 weeks postoperatively so that they do not injure their eyes. They



**Figure 3.** Dogs undergoing cataract surgery receive general anesthesia and a neuromuscular blockade. Dr. Cook uses a Zeiss operating microscope (Carl Zeiss Meditec, Inc., Dublin, CA) and a Phacotron gold phaco unit. She records all intraocular surgery; the monitor is visible (upper left).

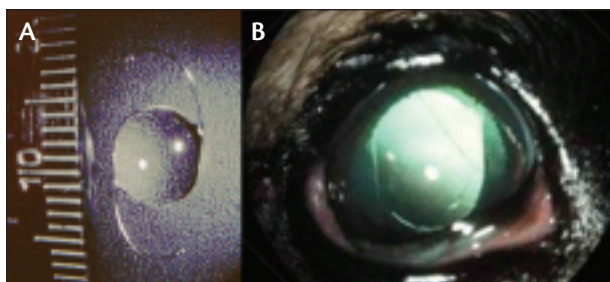


Figure 4. Two weeks after the implantation of a 41.00 D PMMA lens (Ocularvision, Inc.; Solvang, CA) (A), the appearance of this eye is typical (B).

receive topical antibiotics and corticosteroids for 3 to 4 weeks after surgery. Many of the breeds in which cataracts are most common are also predisposed to inherited, primary, angle-closure glaucoma. As my patients cannot verbally alert me to early changes in their vision, periodic monitoring is indicated long after postoperative recovery can be presumed complete.

Complications of canine cataract surgery are uncommon and reflect the intensity with which the canine eye responds to any initiator of inflammation. Some degree of lens-induced uveitis is present in nearly every canine eye with a cataract. This inflammatory response may be accompanied by keratic precipitates and flare that are only partially controlled prior to surgery. Most canine cataracts are mature to hypermature at the time of surgery. Chronic uveitis is often responsible for preexisting posterior synechia, zonular disruption, glaucoma, and retinal degeneration<sup>11-15</sup> (Figure 2). As a result, veterinary ophthalmologists have moved to earlier surgical intervention, but they are still limited by the stage at which dogs are referred for examination. Glaucoma (3%), retinal detachment (4.7%), and some degree of PCO (22%) represent the most common complications affecting patients' visual recovery.<sup>13</sup>

PCO occurs postoperatively in nearly every case. It has been suggested that the profound ability of canine lens epithelial cells to proliferate aggressively would require 100% removal with vacuuming in order to prevent PCO.<sup>14,16</sup> The normal canine lens capsule is 49  $\mu\text{m}$  thick anteriorly and 3.8  $\mu\text{m}$  thick posteriorly, but fibrous metaplasia with capsular opacification and thickening commonly accompanies cataracts. The Nd-YAG laser (2.6 mJ) has been demonstrated experimentally to disrupt the posterior lens capsule, but, clinically, eyes with thickened, opacified tissue in the posterior chamber are much more resistant to laser treatment within the safety margin to avoid damage to the IOL.<sup>17</sup>

Zonular disruption with instability of the capsular bag may prevent the IOL's placement in the bag. In these cases, suture fixation can permit the implantation of an IOL within the ciliary sulcus.<sup>18,19</sup>

## CONCLUSION

Cataract surgery in dogs has many limitations, including the stage at which referral is sought, an intense pre- and postoperative inflammatory response, and limitations associated with veterinary ophthalmologists' ability to assess dogs' vision. Although surgeons are not always able to characterize improved function using objective criteria, they also do not face confounding issues associated with the patient's expectations and (mis)interpretations. Dogs' needs and expectations may be simple, but, in my experience, they clearly appreciate an improved quality of life after cataract surgery. ■

*Cynthia Cook, DVM, PhD, Dip. ACVO, is the founder of Veterinary Vision, which has offices in San Carlos and San Francisco, California. She is active with lecturing, research, and consulting activities in academia and industry. She acknowledged no financial interest in the products or companies mentioned herein. Dr. Cook may be reached at (650) 551-1115; by e-mail at [cscook@veterinaryvision.com](mailto:cscook@veterinaryvision.com); or on the Web at <http://www.veterinaryvision.com>.*



- Davidson MG, Murphy CJ, Nasisse MP, et al. Refractive state of aphakic and pseudophakic eyes of dogs. *Am J Vet Res*. 1993;54:174-177.
- Gaiddon J, Rosolen SG, Steru L, et al. Use of biometry and keratometry for determining optimal power for intraocular lens implants in dogs. *Am J Vet Res*. 1991;52:781-783.
- Cook CS, Peiffer RL, Ginsberg S. A canine intraocular lens. *Proc Am Coll Vet Ophthalmol*. 1985;16.
- Davidson MG. Toward a better canine intraocular lens. *Vet Ophthalmol*. 2001;4:1.
- Schiffner SP, Rantanen NW, Leary GA, Bryan GM. Biometric study of the canine eye, using A-mode ultrasonography. *Am J Vet Res*. 1982;43:826-830.
- Gilger B, Davidson M, Howard PB. Keratometry, ultrasonic biometry, and prediction of intraocular lens power in the feline eye. *Am J Vet Res*. 1998;59:131-134.
- Gilger BC, Whitley RD, Mc Laughlin SA, et al. Clinicopathologic findings after experimental implantation of synthetic intraocular lenses in dogs. *Am J Vet Res*. 1993;54:616-621.
- Nelms S, Davidson MG, Nasisse MP, Glover TL. Comparison of corneal and scleral surgical approaches for cataract extraction by phacoemulsification and intraocular lens implantation in normal dogs. *Veterinary & Comparative Ophthalmology*. 1994;4(2):53-60.
- Warren C. Phaco chop technique for cataract surgery in the dog. *Vet Ophthalmol*. 2004;7:348-351.
- Stuhr CM, Miller PE, Murphy CJ, et al. Effect of intracameral administration of carbachol on the postoperative increase in intraocular pressure in dogs undergoing cataract extraction. *J Amer Vet Med Assn*. 1998;212:1885-1888,1882.
- Miller PE, Lannek EB. Glaucoma following phacoemulsification cataract surgery in dogs: a case-controlled, retrospective study. *Vet Ophthalmol*. 1999;2:263.
- Biros DJ, Gelatt KN, Brooks DE, et al. Glaucoma after cataract surgery (1987-1998): a study of 346 eyes in 220 dogs with long-term follow-up. *Vet Ophthalmol*. 1999;2:256.
- Davidson MG, Nasisse MP, Jamieson VE, et al. Phacoemulsification and intraocular lens implantation: a study of surgical results in 182 dogs. *Progress in Veterinary & Comparative Ophthalmology*. 1991;1(4):233-238.
- Nasisse MP, Dykstra MJ, Cobo LM. Lens capsule opacification in aphakic and pseudophakic eyes. *Graefes Arch Clin Exp Ophthalmol*. 1995;233:63-70.
- Sigle KJ, Nasisse MP. Long-term complications after phacoemulsification for cataract removal in dogs: 172 cases (1995-2002). *J Am Vet Med Assoc*. 2006;228:74-79.
- Davidson MG, Morgan DK, McGahan MC. Effect of surgical technique on in vitro posterior capsule opacification. *J Cataract Refract Surg*. 2000;26:1550-1554.
- Beale AB, Salmon J, Michau TM, et al. Effect of ophthalmic Nd:YAG laser energy on intraocular lenses after posterior capsulotomy in normal dog eyes. *Vet Ophthalmol*. 2006;9:35-40.
- Wilkie DA, Gemensky-Metzler AJ, Colitz CMH, et al. A modified ab externo approach for suture fixation of an intraocular lens implant in the dog. *Vet Ophthalmol*. 2008;11:43-48.
- Nasisse M, Glover TL, Davidson MG, et al. Technique for the suture fixation of intraocular lenses in dogs. *Veterinary & Comparative Ophthalmology*. 1995;5:146-150.